



Current topics

Staging and grading of chronic gastritis

Massimo Rugge MD, Robert M. Genta MD*

Department of Oncological and Surgical Sciences, University of Padova, 35100 Padova, Italy
Department of Pathology, University of Genève, 1211 Genève, Switzerland

Received 22 September 2004; received in revised form 7 November 2004

Keywords:

Gastritis;
Staging and grading;
Gastritis histology

Summary Chronic gastritis is an inflammatory condition of the gastric mucosa that may include structural alterations of the glandular compartment. The semiquantitative scoring systems advocated in the Sydney Systems and the subsequent Atrophy Club Guidelines remain essential for the recognition of the spectrum of the lesions detectable in gastric inflammatory disease. Most practicing pathologists, however, find them too cumbersome to use in their routine diagnostic activities.

In this article, we propose a reporting system for chronic gastritis in staging and grading. Staging would convey information on the topography and extension of the gastric atrophic changes, whereas grading should represent the semiquantitative assessment of the combined severity of both mononuclear and granulocytic inflammation. This system could offer gastroenterologists a more immediate perception of the overall condition of the gastric mucosa while also providing useful information about gastric cancer risk.

© 2005 Elsevier Inc. All rights reserved.

1. Introduction

Chronic gastritis is an inflammatory condition of the gastric mucosa characterized by elementary lesions whose extent and distribution are related to their etiology and host responses. Infection with *Helicobacter pylori* is by far the most common cause of chronic active gastritis worldwide; chemical agents and autoimmune phenomena account for a small proportion of chronic, usually nonactive gastritides. Chronic gastritis is epidemiologically and biologically linked to the development of gastric cancer [1] and *H pylori* is listed as a class I carcinogen [2]. However, the

assessment of cancer risk in individual patients is difficult in part because gastric carcinogenesis is modulated by poorly defined factors, including environment, bacterial strain, and host responses.

Epidemiological data suggest that extent, intensity, and distribution patterns of gastric inflammation and atrophy are consistently related to the incidence of gastric cancer in a population [3–6]. Although these features can be easily evaluated through the histopathological examination of gastric biopsy specimens, we lack a way to translate the pathological information into a standardized report that would (1) convey comprehensive information on the gastric condition and (2) lend itself to a straightforward analysis of cancer risk.

Gastritis can be viewed at two different levels: a basic level represented by the elementary lesions and a hierarchically higher level that defines the disease (ie, the combination and topographical distribution of the different

* Corresponding author. Division de Pathologie Clinique, Hôpitaux Universitaires de Genève, rue Micheli-du-Crest 24, 1211 Genève, Switzerland.

E-mail address: robert.genta@medecine.unige.ch (R.M. Genta).

elementary lesions). Both the 1990 original Sydney System [7] and its updated 1994 version (also known as the Houston-updated Sydney System) [8] provided a structure to describe and quantify the elementary lesions, that is, the inflammatory cell populations, and the accompanying changes of the epithelial district.

Although the Houston-updated Sydney System's guidelines are now widely used [9], the interobserver agreement among pathologists has shown variable levels of consistency, particularly with regards to atrophy [10,11]. In an attempt to correct this problem, an international group of pathologists (Atrophy Club 2000) revisited the spectrum of gastric atrophy and intestinal metaplasia (IM) [12,13]. A new definition of atrophy, which includes a metaplastic and a nonmetaplastic category, was proposed, and new criteria for the 2 main phenotypes of chronic gastritis (nonatrophic and atrophic) were established [12,13]. The schema for this classification is depicted in Fig. 1. Gastrointestinal pathologists who tested this classification were able to obtain a highly satisfactory level of interobserver variation [13]. To our knowledge, no studies regarding the consistency of usage of the Atrophy Club criteria among general pathologists have been published to date.

As early as 1955, Basil Morson [14] observed that “the incidence and the extent of IM is greatest in stomachs containing carcinomas and least in those with duodenal ulcer, with cases of gastric ulcer taking an intermediate position.” Later, Pelayo Correa [15,16] demonstrated that patchy areas of atrophic-metaplastic changes in the antral

and oxyntic mucosa (ie, multifocal atrophic gastritis [MAG]) frequently coexisted with gastric ulcer and were the most frequent setting for gastric adenocarcinoma. On the basis of these and other observations [17], the Sydney Systems took into account the topographical distribution of the elementary lesions in the different gastric compartments and recommended that multiple endoscopic biopsy samples be taken from predefined sites of the stomach [8]. Five main sites were considered necessary: (1) greater and lesser curvature of the distal antrum (mucus-secreting mucosa), (2) greater and lesser curvature of the proximal corpus (oxyntic mucosa), and (3) lesser curvature at the *incisura angularis*, where the earliest atrophic-metaplastic changes tend to occur [18,19]. The scores of the elementary lesions found in individual biopsy samples are averaged for each gastric compartment and used to characterize different patterns of gastritis (eg, antral-predominant nonatrophic, antrum-restricted atrophic). These pattern-based categorizations may allow placing patients on approximate points of the natural history of chronic gastritis, from the reversible inflammatory lesions (mostly limited to the antrum) at the one end to the extensive atrophic changes associated with high risk for gastric cancer at the other [4,20-22].

This article puts forward a proposal for a systematic approach to this categorization. Building on our current understanding of the morphological alterations of gastritis and their evolution, we suggest that—as in chronic hepatitis [23,24]—it could be useful to report the phenotypes of long-standing gastritis in *grading* and *staging*. *Grading* would express the cumulative intensity of the inflammatory components, whereas *staging* would convey information on the anatomical extent of the atrophic-metaplastic changes related to cancer risk.

Self-limiting gastritides, also referred to as acute gastritides or gastropathies, are a group of conditions generally characterized by limited inflammatory responses and variable erosive and hemorrhagic lesions. Most often caused by environmental injury (eg, chemical), they tend to undergo rapid recovery after the damaging agents are removed. Such gastropathies have no known relationship with cancer, and therefore, are not included in this discussion.

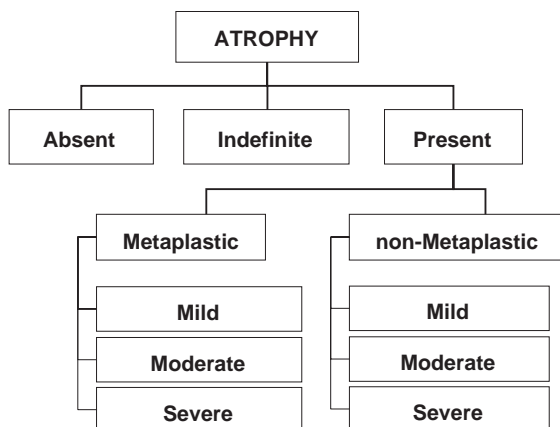


Fig. 1 Classification of atrophy proposed by the Atrophy Club 2000 (13). The concept of “absence of appropriate (ie, native to the specific area) glands” introduced in the definition allows the inclusion a metaplastic category, represented by the replacement of native glands by either intestinal-type epithelium or pyloric-type glands. Non-metaplastic atrophy consists of a decreased density of native gland units with a corresponding increase in the extraglandular extracellular matrix. These two categories may, and often do, coexist in the same patient. “Indefinite for atrophy” is a preliminary categorization to be used whenever a dense inflammatory infiltrate prevents a clear distinction between the non-atrophic and atrophic phenotype.

2. The phenotypes of gastritis

Chronic gastritis can be atrophic or nonatrophic. Each of these two main categories encompasses several clinicopathologic entities with different patterns of inflammatory and epithelial alterations.

2.1. Non-atrophic gastritis

2.1.1. Antral-predominant non-atrophic gastritis

This pattern (synonymous with hypersecretory, diffuse antral, or superficial antral gastritis) [16] is the most common expression of *H pylori* gastritis in the Western

world. It is characterized by (1) absence of atrophy, (2) a moderately to severely inflamed antrum and (3) a normal to mildly inflamed corpus. This condition is associated with either normal or increased acid secretion. Most patients with antrum-predominant gastritis experience no symptoms; they do, however, have an estimated lifetime risk of duodenal ulcer of ~20%, and possibly a minimally increased risk of adenocarcinoma of the distal stomach when compared to the noninfected population [25].

2.1.2. Nonatrophic pangastritis

In some subjects infected with *H pylori*, marked inflammation is distributed throughout the stomach, with little or no difference between antrum and corpus. Particularly frequent in poorly sanitized areas where *H pylori* is highly endemic, pangastritis is widely believed to be the background on which atrophy eventually develops [26]. Although this hypothesis is founded on reasonable grounds, we are not aware of any studies that substantiate this proposition.

2.2. Atrophic chronic gastritis

Gastric mucosal atrophy is defined as the loss of appropriate glands [13]. This loss occurs when glands damaged by inflammation are replaced either by connective tissue (scarring) or by glandular structures inappropriate for location (metaplasia). Most often, the metaplastic transformation assumes the phenotype of the glands lined by intestinal-type epithelium (IM), but in the oxyntic mucosa, it may also take the form of mucin-secreting antral glands (pseudopyloric metaplasia). The histological criteria for scoring atrophic-metaplastic changes in both the antral and oxyntic mucosa have been extensively described [13], and visual analogue scales have been proposed as a reference standard [27]. Even when extensive biopsy protocols are used, inevitable sampling errors may affect the documentation of the atrophic foci, which are frequently patchy. In the absence of more accurate methods, however, we are bound to accept the intuitive premise that the greater the extension of atrophy, the more likely it is that it is biopsied, and therefore, that the extent and distribution detected by the recommended 5-sample biopsy protocol are a valid representation of the true mucosal atrophy.

2.2.1. Antrum-restricted atrophic gastritis

In the Western world, when atrophy is detected in biopsy specimens from dyspeptic patients, it is most frequently located in the antral biopsy samples. In such patients, atrophic-metaplastic changes are the consequence of current (or past) *H pylori* infection. The biopsy set will show (1) patchy metaplastic atrophy restricted to the distal mucin-secreting mucosa (including the *incisura angularis*) coexisting with moderate to severe inflammation and (2) a normal or mildly inflamed corpus, with no atrophic changes.

2.2.2. Corpus-restricted (corpus-predominant) atrophic gastritis

In the oxyntic mucosa, atrophic-metaplastic changes can be detected in the absence of any coexisting atrophic changes of the distal stomach or in association with atrophic foci of the antral mucosa. The former condition is considered virtually pathognomonic of an autoimmune etiology and it is associated with an increased cancer risk [28,29]. Rarely, autoimmune atrophy (by definition, affecting only oxyntic glands) may coexist with antral atrophy resulting from a concurrent *H pylori* infection. In these cases, pathogenetically different atrophic changes may topographically merge with each other (corpus-autoimmune and *H pylori*-associated atrophic gastritis), resulting in a substantially increased cancer risk.

2.2.3. Multifocal atrophic gastritis

Multifocal atrophic gastritis (MAG) (formerly referred to as “environmental chronic atrophic gastritis”) is most prevalent in populations that are (or have been until recently) living in suboptimal sanitary conditions, including much of southern and eastern Asia, Latin America, and several parts of central, eastern, and southern Europe [30-32]. Socioeconomic factors may be a surrogate for other unknown agents or biological situations that modulate the evolution of gastritis, because there are notable epidemiological exceptions to this association. For example Japan, a leading economic power with high levels of sanitation and personal hygiene, has one of the world’s highest prevalence of atrophic gastritis and a high incidence of gastric adenocarcinoma [33]. In contrast, Equatorial Africa, in spite of its precarious socioeconomic texture, inadequate sanitary standards, and a prevalence of *H pylori* close to 90%, reportedly has a low prevalence of atrophic gastritis as well as a low incidence of gastric adenocarcinoma [34,35].

Atrophic gastritis is a risk factor for gastric noninvasive neoplasia (dysplasia) and intestinal-type adenocarcinoma [36]. It also predisposes to gastric ulcer [37-39]. In MAG, biopsy specimens show foci of atrophic-metaplastic changes in both antral and corpus mucosa. In contrast to antrum-restricted atrophic gastritis, MAG may display severe inflammation in the oxyntic mucosa, and acid secretion may be reduced, suggesting a more advanced disease. The nosological relationship between antrum-restricted atrophy and MAG remains to be determined; although it is possible that they are biologically different diseases, it seems more likely that they represent different stages of the same disease. Some data suggest that in *H pylori*-chronic gastritis, the stage of antrum-restricted atrophy precedes the more extensively spreading (multifocal) atrophy, but this hypothesis awaits verification.

2.2.4. Atrophic pangastritis

Atrophic pangastritis (similar magnitude of atrophy and inflammation in antrum and corpus) is likely to represent an advanced stage of MAG, with which it shares the

		CORPUS			
		No Inflammation (G0)	Mild Inflammation (G1)	Moderate Inflammation (G2)	Severe Inflammation (G3)
A N T R U M	No Inflammation (G0)	GRADE 0	GRADE I	GRADE II	GRADE II
	Mild Inflammation (G1)	GRADE I	GRADE II	GRADE II	GRADE III
	Moderate Inflammation (G2)	GRADE II	GRADE II	GRADE III	GRADE IV
	Severe Inflammation (G3)	GRADE II	GRADE III	GRADE IV	GRADE IV

Fig. 2 Grading: intensity of the inflammatory cells (lymphocytes, plasma cells, and granulocytes) within the lamina propria is graded as absent (0), mild (1), moderate (2) and severe (3) according to the visual analogue scales of the Updated Sydney System. The final grade of inflammation results from the combination of the grades of the inflammatory lesions in antral and corpus mucosa.

epidemiological characteristics. Atrophic pangastritis is the most prevalent setting for both noninvasive and invasive gastric neoplasia [26,40,41]. In the stomach, the field cancerization process is mucosal atrophy: the atrophic areas with their metaplastic glands are the anatomic structures prone to the phenotypical and genotypic alterations leading to cancer. The field cancerization theory provides the rationale for the linear relationship between the extent of atrophic changes and the risk of cancer [42].

3. Generating a clinically helpful histology report

Using the framework provided by the Sydney System’s and the Atrophy Club’s analytic approach, we have

generated a proposal for a grading and staging scheme that integrates the relevant histopathological data gathered and interpreted by the pathologist and delivers them in the form of a simple, yet information-rich, report. We submit that his scheme could do for chronic gastritis what the grading and staging chronic hepatitis system introduced by the International Group of the Hepatologists has done for chronic hepatitis, making prognostically significant and reproducible information immediately available in the clinical practice [23,24].

Grading is a measure of the severity of the inflammatory lesions. Although other grading systems consider separately the mononuclear from the neutrophilic infiltrate, there is no evidence that this distinction is clinically relevant. We propose that grading should represent the semiquantitative assessment of the combined severity of mononuclear and

		CORPUS			
		No Atrophy (score 0)	Mild Atrophy (score 1)	Moderate Atrophy (score 2)	Severe Atrophy (score 3)
A N T R U M	No Atrophy (score 0) (including incisura angularis)	STAGE 0	STAGE I	STAGE II	STAGE III
	Mild Atrophy (score 1) (including incisura angularis)	STAGE I	STAGE II	STAGE II	STAGE III
	Moderate Atrophy (score 2) (including incisura angularis)	STAGE II	STAGE II	STAGE III	STAGE IV
	Severe Atrophy (score 3) (including incisura angularis)	STAGE III	STAGE III	STAGE IV	STAGE IV

Fig. 3 Staging: atrophy is defined as loss of appropriate glands (with or without IM). In each compartment (ie, mucous-secreting antral and oxyntic/corpus mucosa), atrophy is scored in a 4 tiered scale (0-3), according to the visual analogue scale of the Updated Sydney System.

granulocytic inflammation scored in both antral and oxyntic biopsy samples. Grades range from 0 (absence of inflammatory cells in any of the specimens) to 4 (a very dense infiltrate in all the biopsy samples) (Fig. 2).

Staging refers to the extent of atrophy with or without IM. The stage of chronic gastritis is related to both its duration and to the host's response to the etiological agent(s) and may have implications for the prognosis and management of the patient. Some studies suggested that the histochemical phenotype of IM is associated with a cancer risk increasing progressively from type I to type III [43,44]. Because a greater extension of metaplasia is associated with a greater proportion of type III IM [40], we uphold the recommendation of the Updated Sydney System discouraging the use of histochemical phenotyping to determine the type of metaplasia. Atrophy should be assessed using the histological criteria detailed by the Atrophy Club, which have been validated and shown to be reproducible [13]. Fig. 3 shows how the scores from antral and oxyntic mucosal biopsy sites can then be combined and reported using a scale ranging from 0 (absence of atrophy and metaplasia) to 4 (pan-atrophy involving all antral and oxyntic samples).

4. Conclusions

The article reporting the Updated Sydney System, published in October 1996, has recently reached the 1000-citation milestone [9], indicating that the semiquantitative scoring system it advocated remains a useful tool for clinical research. Nevertheless, the very same pathologists who use it when assessing biopsies for clinical studies find it too cumbersome to use in their routine diagnostic activities. We suggest that the method proposed here is both feasible and practical. When a satisfactory set of gastric biopsies is available, staging and grading (preceded by a description of the histological findings in the biopsy samples) could represent the concluding message of the histological report.

An initial informal testing of this proposed scheme has been well received by gastroenterologists in our respective institutions. Once accepted and disseminated, it could offer clinicians an overall perception of the gastric disease, while also providing potentially useful information about cancer risk. Ten years ago, a similar nomenclature was proposed for reporting chronic hepatitis. Tested in the routine practice and now used by virtually all hepatopathologists, staging and grading have been proven to be both reproducible and clinically useful. Our hope is that this proposal stimulates a constructive debate and that this scheme can eventually be tested in a variety of clinicoepidemiological settings to determine (1) whether pathologists can use it with a satisfactory interobserver consistency and (2) whether the prognostic value that we have hypothesized can be confirmed in the field.

References

- [1] Correa P. A human model of gastric carcinogenesis. *Cancer Res* 1988;48:3554-60.
- [2] Anonymous. Schistosomes, liver flukes and *Helicobacter pylori*. IARC Working Group on the evaluation of carcinogenic risks to humans. Lyon, 7-14 June 1994. IARC Monogr Eval Carcinog Risks Hum 1994;61:1-241.
- [3] Correa P, Cuello C, Duque E, et al. Gastric cancer in Colombia. III. Natural history of precursor lesions. *J Natl Cancer Inst* 1976;57:1027-35.
- [4] Sipponen P, Kekki M, Siurala M. Atrophic chronic gastritis and intestinal metaplasia in gastric carcinoma. Comparison with a representative population sample. *Cancer* 1983;52:1062-8.
- [5] You WC, Zhang L, Gail MH, et al. Precancerous lesions in two counties of China with contrasting gastric cancer risk. *Int J Epidemiol* 1998;27:945-8.
- [6] Correa P. The biological model of gastric carcinogenesis. *IARC Sci Publ* 2004;301-10.
- [7] Price AB. The Sydney system: histological division. *J Gastroenterol Hepatol* 1991;6:209-22.
- [8] Dixon MF, Genta RM, Yardley JH, et al. Classification and grading of gastritis. The updated Sydney system. International workshop on the histopathology of gastritis, Houston 1994. *Am J Surg Pathol* 1996;20:1161-81.
- [9] ISI web of science—Citation Index. Science Citation Index Expanded (SCI-EXPANDED)-1945-present. 2004.
- [10] Offerhaus GJ, Price AB, Haot J, et al. Observer agreement on the grading of gastric atrophy. *Histopathology* 1999;34:320-5.
- [11] Aydin O, Egilmez R, Karabacak T, et al. Interobserver variation in histopathological assessment of *Helicobacter pylori* gastritis. *World J Gastroenterol* 2003;9:2232-5.
- [12] Ruiz B, Garay J, Johnson W, et al. Morphometric assessment of gastric antral atrophy: comparison with visual evaluation. *Histopathology* 2001;39:235-42.
- [13] Rugge M, Correa P, Dixon MF, et al. Gastric mucosal atrophy: interobserver consistency using new criteria for classification and grading. *Aliment Pharmacol Ther* 2002;16:1249-59.
- [14] Morson BC. Intestinal metaplasia in the gastric mucosa. *Br J Cancer* 1955;9:365-76.
- [15] Correa P. The epidemiology and pathogenesis of chronic gastritis: three etiologic entities. *Front Gastrointest Res* 1980;6:98-108.
- [16] Correa P. Chronic gastritis: a clinico-pathological classification. *Am J Gastroenterol* 1988;83:504-9.
- [17] Sugimura T, Sugano H, Terada M, et al. First international workshop of the Princess Takamatsu cancer research fund: intestinal metaplasia and gastric cancer. *Mol Carcinog* 1994;11:1-7.
- [18] Kimura K. Chronological transition of the fundic-pyloric border determined by stepwise biopsy of the lesser and greater curvatures of the stomach. *Gastroenterology* 1972;63:584-92.
- [19] Rugge M, Cassaro M, Pennelli G, et al. Atrophic gastritis: pathology and endoscopy in the reversibility assessment. *Gut* 2003;52:1387-8.
- [20] Sipponen P, Kekki M, Haapakoski J, et al. Gastric cancer risk in chronic atrophic gastritis: statistical calculations of cross-sectional data. *Int J Cancer* 1985;35:173-7.
- [21] Sipponen P, Seppala K, Aarinen M, et al. Chronic gastritis and gastroduodenal ulcer: a case control study on risk of coexisting duodenal or gastric ulcer in patients with gastritis. *Gut* 1989;30:922-9.
- [22] Sipponen P, Riihelä M, Hyvärinen H, et al. Chronic non-atrophic ('superficial') gastritis increases the risk of gastric carcinoma. A case-control study. *Scand J Gastroenterol* 1994;29:336-40.
- [23] Desmet VJ, Gerber M, Hoofnagle JH, et al. Classification of chronic hepatitis: diagnosis, grading and staging. *Hepatology* 1994;19:1513-20.
- [24] Ishak K, Baptista A, Bianchi L, et al. Histological grading and staging of chronic hepatitis. *J Hepatol* 1995;22:696-9.

- [25] Graham DY. *Helicobacter pylori* infection in the pathogenesis of duodenal ulcer and gastric cancer: a model. *Gastroenterology* 1997;113:1983-91.
- [26] Miehke S, Hackelsberger A, Meining A, et al. Severe expression of corpus gastritis is characteristic in gastric cancer patients infected with *Helicobacter pylori*. *Br J Cancer* 1998;78:263-6.
- [27] Genta RM. Recognizing atrophy: another step toward a classification of gastritis. *Am J Surg Pathol* 1996;20(Suppl 1): S23-S30.
- [28] Strickland RG, Mackay IR. A reappraisal of the nature and significance of chronic atrophic gastritis. *Am J Dig Dis* 1973; 18:426-40.
- [29] Capella C, Fiocca R, Cornaggia M, et al. Autoimmune gastritis. In: Graham DY, Genta RM, Dixon MF, editors. *Gastritis*. Philadelphia: Lippincott Williams & Wilkins; 1999. p. 79-96.
- [30] Yang GY, Zhang YC, Liu XD, et al. Geographic pathology on the precursors of stomach cancer. *J Environ Pathol Toxicol Oncol* 1992; 11:339-44.
- [31] Genta RM, Gürer IE, Graham DY. Geographical pathology of *Helicobacter pylori* infection: is there more than one gastritis? *Ann Med* 1995;27:595-9.
- [32] El Zimaity HMT, Gutierrez O, Kim JG, et al. Geographic differences in the distribution of intestinal metaplasia in duodenal ulcer patients. *Am J Gastroenterol* 2001;96:666-72.
- [33] Kimura K. Gastritis and gastric cancer. *Asia. Gastroenterol Clin North Am* 2000;29:609-21.
- [34] Kuipers EJ, Meijer GA. *Helicobacter pylori* gastritis in Africa. *Eur J Gastroenterol Hepatol* 2000;12:601-3.
- [35] Segal I, Ally R, Mitchell H. Gastric cancer in sub-Saharan Africa. *Eur J Cancer Prev* 2001;10:479-82.
- [36] Rugge M, Leandro G, Farinati F, et al. Gastric epithelial dysplasia. How clinicopathologic background relates to management. *Cancer* 1995;76:376-82.
- [37] Meister H, Holubarsch C, Haferkamp O, et al. Gastritis, intestinal metaplasia and dysplasia versus benign ulcer in stomach and duodenum and gastric carcinoma—a histotopographical study. *Pathol Res Pract* 1979;164:259-69.
- [38] Sipponen P. Natural history of gastritis and its relationship to peptic ulcer disease. *Digestion* 1992;51(Suppl 1):70-5.
- [39] Skinner JM, Heenan PJ, Whitehead R. Atrophic gastritis in gastrectomy specimens. *Br J Surg* 1975;62:23-5.
- [40] Cassaro M, Rugge M, Gutierrez O, et al. Topographic patterns of intestinal metaplasia and gastric cancer. *Am J Gastroenterol* 2000;95: 1431-8.
- [41] Meining A, Bayerdorffer E, Muller P, et al. Gastric carcinoma risk index in patients infected with *Helicobacter pylori*. *Virchows Arch* 1998;432:311-4.
- [42] Garcia SB, Park HS, Novelli M, et al. Field cancerization, clonality, and epithelial stem cells: the spread of mutated clones in epithelial sheets. *J Pathol* 1999;187:61-81.
- [43] Filipe MI, Munoz N, Matko I, et al. Intestinal metaplasia types and the risk of gastric cancer: a cohort study in Slovenia. *Int J Cancer* 1994;57:324-9.
- [44] Wu MS, Shun CT, Lee WC, et al. Gastric cancer risk in relation to *Helicobacter pylori* infection and subtypes of intestinal metaplasia. *Br J Cancer* 1998;78:125-8.